

Sirolimus-Induced Acneiform Eruption

N. Kunzle^a J.-P. Venetz^b M. Pascual^b R.G. Panizzon^a E. Laffitte^a

^aDepartments of Dermatology and Venerology, DHURDV, and ^bTransplant Center, Centre Hospitalier Universitaire Vaudois (CHUV), Lausanne, Switzerland

Key Words

Sirolimus · Acne · Drug eruption · Transplantation

Abstract

Sirolimus is a new immunosuppressive agent used to prevent rejection in renal allograft recipients in order to reduce the need of potentially nephrotoxic calcineurin inhibitors (cyclosporine, tacrolimus). The cutaneous side effects of sirolimus are not well known and they may have been underestimated. We report 2 cases of follicular acneiform eruptions induced by sirolimus in renal allograft recipients. This dermatologic complication was severe and difficult to treat, and resolved only after discontinuation of sirolimus.

Copyright © 2005 S. Karger AG, Basel

Introduction

Sirolimus (rapamycin, Rapamune[®]) is a new immunosuppressive agent which is a macrocyclic triene antibiotic produced by the actinomycete *Streptomyces hygriscopicus*. Unlike cyclosporine and tacrolimus, sirolimus does not affect the calcineurin pathway. This drug is an inhibitor of the mammalian target of rapamycin (mTOR), a multifunctional serine-threonine kinase that acts on IL-2-mediated signal transduction pathways, which is a central regulator of cell growth, proliferation, and apoptosis [1]. As an effective alternative to calcineurin inhibitors, sirolimus is indicated for preventing rejection in renal allograft recipients [2].

The association between sirolimus and dermatologic complications is not well known and may have been underestimated. We report 2 cases of follicular acneiform eruptions induced by sirolimus after renal transplantation. This side effect was severe enough to require treatment discontinuation, and this was followed by complete resolution of the skin lesions.

Case Reports

Patient 1

A 33-year-old woman, without history of acne or skin lesion, received a living-related (from her mother) renal allograft in 1994 for end-stage renal disease (ESRD) due to focal segmental glomerulosclerosis. Her initial immunosuppression consisted of cyclosporine and steroids. Withdrawal of steroids was achieved 1 year after transplantation. Seven years later, because of a progressive allograft dysfunction, cyclosporine was replaced by mycophenolate mofetil and low-dose tacrolimus. Subsequently, a renal biopsy showed calcineurin inhibitor-induced toxicity and, therefore, tacrolimus was replaced by sirolimus (2–3 mg/day) to target drug trough levels between 4 and 12 µg/l. At the time of the switch, the patient was also receiving lisinopril, simvastatin and weekly injections of erythropoietin. Two weeks after starting sirolimus, she developed multiple papules and pustules on erythematous fields localized on the forehead, cheeks and throat (fig. 1). Several microbiological swabs were all negative. The diagnosis of papulopustular acneiform eruption was made. Topical treatment with

benzoyl peroxide, erythromycin, and then adapalene followed by oral treatment with doxycycline (2 × 50 mg/day) was ineffective. Microcytic anemia also developed following the conversion to sirolimus. In light of the chronology and the nonresponse to the treatment administered, acneiform eruption induced by sirolimus was suspected; therefore, the drug was discontinued and replaced by tacrolimus. The skin lesions completely disappeared within 2 weeks.

Patient 2

A 36-year-old woman, who suffered from acne treated by isotretinoin during adolescence, received a first cadaveric renal allograft in 2002 for ESRD secondary to hemolytic uremic syndrome. The initial immunosuppression consisted of an association of basiliximab induction, tacrolimus, steroids, and mycophenolate mofetil. Because of slow graft function and histological signs of acute tacrolimus toxicity, tacrolimus was replaced by sirolimus 20 days after transplantation. The trough levels of sirolimus were maintained between 6 to 12 µg/l (4–5 mg/day). Steroids were tapered progressively during the first year, down to 2.5 mg/day. The other medications consisted of valsartan, perindopril, clonidine, atenolol, furosemide and lorazepam. The patient developed progressively, 2 weeks after the introduction of sirolimus, monomorphic erythematous papules on the cheeks and throat (fig. 2). In light of the chronology and the monomorphic aspect of the lesions, acneiform eruption caused by sirolimus was suspected, but the patient was maintained on sirolimus therapy to avoid calcineurin inhibitor use. One year later,

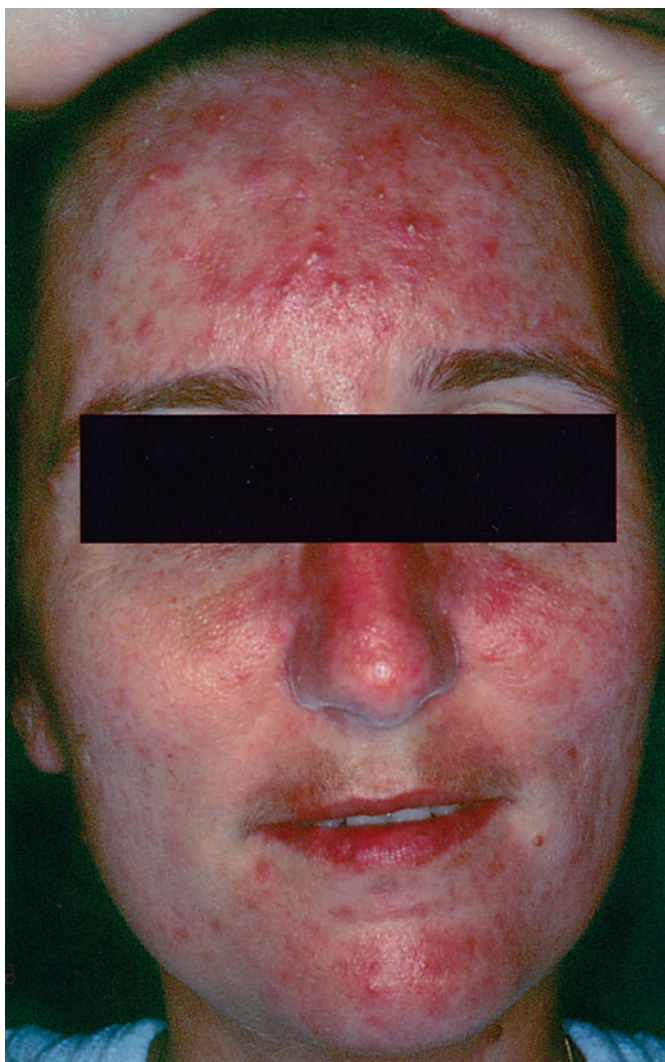


Fig. 1. Patient 1. Papules and pustules on the forehead, cheeks and throat.

her allograft function deteriorated and a renal allograft biopsy was performed, which showed an acute humoral rejection with C4d deposits in peritubular capillaries and antidonor antibodies in serum. Sirolimus was discontinued and a rescue therapy was attempted with plasmapheresis and thymoglobulin, tacrolimus, steroids and mycophenolate [3]. The skin lesions disappeared after 10–15 days. Unfortunately, her clinical course was complicated by the recurrence of hemolytic uremic syndrome, possibly triggered by re-initiation of tacrolimus therapy. Therefore, tacrolimus was replaced by sirolimus, and the acneiform lesions recurred within 1 week. Three weeks later,

due to rapidly progressive renal failure with severe hypertension, she underwent graft nephrectomy and sirolimus was discontinued. The cutaneous lesions disappeared within a few days (fig. 3). Currently, the patient is on maintenance hemodialysis, with no skin lesions.

Discussion

The morphology of the cutaneous lesions in our 2 patients evoked the diagnosis of acneiform eruption, despite the lack of comedos and microcysts. Its unexpected appearance at an age other than adoles-

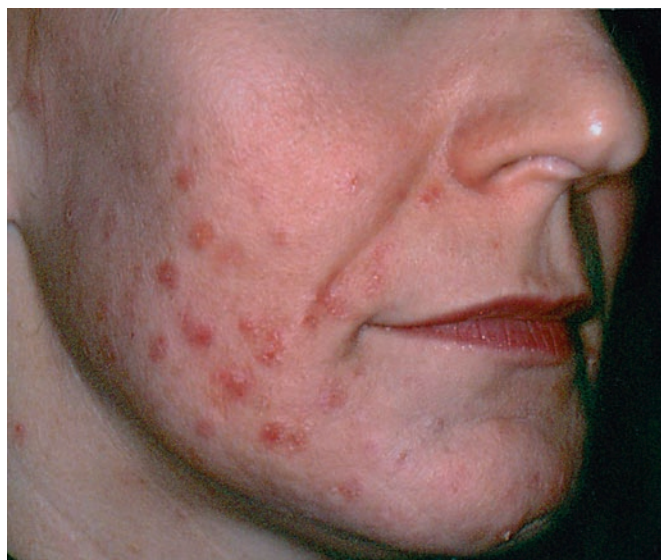

Fig. 2. Patient 2. Monomorphic erythematous papules on the cheeks and throat.

cence, the relatively more inflammatory (than retentional) lesions, the rapid aggravation and the involvement of areas slightly different from those of classic seborrheic areas led to the suspicion of drug-induced acneiform eruption.

Drugs represent the principal etiology in cases of acneiform eruption appearing after adolescence and numerous substances have been implicated: corticosteroids, ACTH, androgens, oral contraceptives, thyroid hormones, halogens, lithium salts, vitamin B₁₂, some antibiotics, tuberculostatics, antiepileptics and neuroleptics [4].

The development of acneiform lesions in organ-transplant recipients is relatively common and is usually attributed to the use of corticosteroids, in general early after transplantation when dosages are higher [5]. Some rare cases of acneiform eruption due to cyclosporine and azathioprine have also been reported [6].

Sirolimus-related complications include hypercholesterolemia and hypertriglyceridemia, thrombocytopenia, microcytic anemia, mouth ulcers and pulmonary toxicity [2, 7], but cutaneous side effects may have been underestimated. Indeed, in a cohort of 71 renal transplant recipients under sirolimus, 48% developed acneiform lesions [8]. In another recent retrospective study in 175 liver transplant recipients, ‘dermatitis’ (acne type) was seen in 13% of the patients [9].

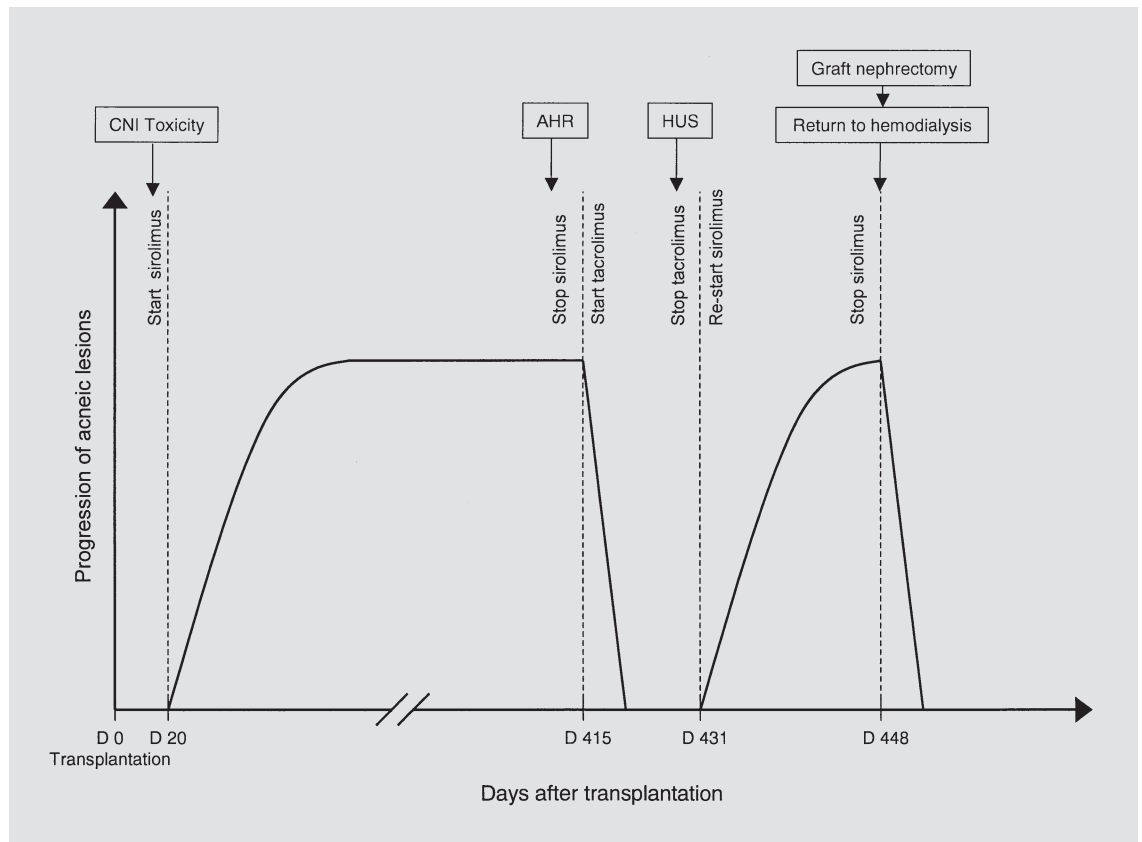


Fig. 3. Patient 2. Temporal relationship between sirolimus use and the acneiform eruption. CNI = Calcineurin inhibitors; AHR = acute humoral rejection; HUS = hemolytic uremic syndrome.

The frequency of adverse effects such as hyperlipidemia, hypercholesterolemia, thrombocytopenia and aphthous stomatitis are dose-dependent [10]. The frequency of acneiform eruption, however, does not appear to be dose-related. A few years ago, Kahan [11] compared the efficacy of two doses of sirolimus (2 or 5 mg/day) with azathioprine in combination with cyclosporine and steroids. They found an acne incidence of approximately 20% without any difference between the two doses of sirolimus [11].

Interestingly, acne-like follicular eruptions have also been observed after CCI-799 administration, another mTOR inhibitor which is a water-soluble ester form of sirolimus with promising antitumor activity [12]. The pathophysiology of those eruptions associated with mTOR inhibitors is still unclear. Similar acneiform eruptions have recently been observed in up to 75% of patients treated by cetuximab or gefitinib [13, 14], two new anticancer agents. These

molecules are both inhibitors of the epidermal growth factor receptor (EGF-R): cetuximab is a monoclonal antibody targeting EGF-R, while gefitinib is a specific intracellular inhibitor of EGF-R-dependent tyrosine kinase. EGF-R is implicated in the development and progression of cancer, but also plays a central role in normal differentiation and development of the hair follicle [15]. Direct EGF-R blockade in the pilosebaceous unit could lead to the appearance of follicular acne-like eruption in patients treated with EGF-R inhibitors. In sirolimus-induced acneiform eruptions, the lesions are rather similar to those observed with EGF-R inhibitors, and *in vitro* studies have shown that rapamycin can interfere with some EGF-R-associated intracellular kinases, and inhibits some EGF-induced cell transformation [16]. We therefore speculate that inhibition of the EGF-R pathway may be involved in sirolimus-induced acneiform eruptions [14].

In our cases, the sudden appearance of acneiform lesions a few weeks after the administration of sirolimus while all other medications remained unchanged, the resolution of skin lesions after withdrawal of the drug and the reappearance during readministration to one of the patients strongly incriminate sirolimus as the causative agent of the acneiform eruption. In particular, the close temporal relationship between sirolimus use and the skin lesions of the second case cannot be coincidental. In such cases, the lesions might be severe and difficult to treat, i.e. a refractory acne with important alteration of the quality of life, as in our 2 patients. In case of treatment failure with a topical antiacne agent or oral cyclins, great care should be taken before using oral retinoids because of the risk of inducing acute acne [17]. Withdrawal of sirolimus should, therefore, be considered as a therapeutic option for patients suffering from refractory sirolimus-induced acneiform lesions.

References

- 1 Vasquez EM: Sirolimus: a new agent for prevention of renal allograft rejection. *Am J Health Syst Pharm* 2000;57:437-448; quiz 449-451.
- 2 Kreis H, Oberbauer R, Campistol JM, Mathew T, Daloz P, Schena FP, et al: Long-term benefits with sirolimus-based therapy after early cyclosporine withdrawal. *J Am Soc Nephrol* 2004;15:809-817.
- 3 Magee CC, Pascual M: Update in renal transplantation. *Arch Intern Med* 2004;164:1373-1388.
- 4 Bedane C, Souyri N: Induced acne (in French). *Ann Dermatol Venereol* 1990;117:53-58.
- 5 O'Connell BM, Abel EA, Nickoloff BJ, Bell BJ, Hunt SA, Theodore J, et al: Dermatologic complications following heart transplantation. *J Heart Transplant* 1986;5:430-436.
- 6 el-Shahawy MA, Gadallah MF, Massry SG: Acne: a potential side effect of cyclosporine A therapy. *Nephron* 1996;72:679-682.
- 7 Pham PT, Pham PC, Danovitch GM, Ross DJ, Gritsch HA, Kendrick EA, et al: Sirolimus-associated pulmonary toxicity. *Transplantation* 2004;77:1215-1220.
- 8 Mahé E, Morelon E, Ducasse M, Kreis H, De Prost Y, Bodemer C: Evaluation dermatologique de 71 patients transplantés rénaux sous immunosuppression comprenant du sirolimus. *Ann Dermatol Venereol* 2003;130:4S65.
- 9 Montalbano M, Neff GW, Yamashiki N, Meyer D, Bettiol M, Slapak-Green G, et al: A retrospective review of liver transplant patients treated with sirolimus from a single center: an analysis of sirolimus-related complications. *Transplantation* 2004;78:264-268.
- 10 Reitamo S, Spuls P, Sassolas B, Lahfa M, Claudy A, Griffiths CE: Efficacy of sirolimus (rapamycin) administered concomitantly with a subtherapeutic dose of cyclosporin in the treatment of severe psoriasis: a randomized controlled trial. *Br J Dermatol* 2001;145:438-445.
- 11 Kahan BD: Efficacy of sirolimus compared with azathioprine for reduction of acute renal allograft rejection: a randomised multicentre study. The Rapamune US Study Group. *Lancet* 2000;356:194-202.
- 12 Raymond E, Alexandre J, Faivre S, Vera K, Materman E, Boni J, et al: Safety and pharmacokinetics of escalated doses of weekly intravenous infusion of CCI-779, a novel mTOR inhibitor, in patients with cancer. *J Clin Oncol* 2004;22:2336-2347.
- 13 Dereure O: Skin reactions related to treatment with anticytokines, membrane receptor inhibitors and monoclonal antibodies. *Expert Opin Drug Saf* 2003;2:467-473.
- 14 Laffitte E, Saurat JH: Kinase inhibitor-induced pustules. *Dermatology* 2005;211:305-306.
- 15 Mimeault M, Bonenfant D, Batra SK: New advances on the functions of epidermal growth factor receptor and ceramides in skin cell differentiation, disorders and cancers. *Skin Pharmacol Physiol* 2004;17:153-166.
- 16 Nomura M, He Z, Koyama I, Ma WY, Miyamoto K, Dong Z: Involvement of the Akt/mTOR pathway on EGF-induced cell transformation. *Mol Carcinog* 2003;38:25-32.
- 17 Marcusson JA, Tyden G: Acne conglobata in transplant patients treated with isotretinoin. *Br J Dermatol* 1988;118:310-312.